

The utility of cerebral oxygenation monitoring in premature neonates

Saudamini Nesargi

St. John's Medical College Hospital, Department of Neonatology, Bangalore, Karnataka, India

 <https://orcid.org/0000-0002-9611-4322>

Alexander Nitsch

Corresponding author: janalexander.nitsch@usz.ch


Department of Neonatology, University of Zürich, Zürich, Switzerland

 <https://orcid.org/0000-0002-5740-9451>

Martin Wolf

Department of Neonatology, Biomedical Optics Research Laboratory, University Hospital Zürich, Zürich, Switzerland

 <https://orcid.org/0000-0001-7525-891X>

 DOI: <https://doi.org/10.20883/medical.e485>

Keywords: NIRS, near-infrared spectroscopy, preterm, neonate, neonatology, cerebral oxygenation

Published: 2020-12-30

How to cite: Nesargi S, Nitsch A, Wolf M. The utility of cerebral oxygenation monitoring in premature neonates. *JMS* [Internet]. 2020 Dec 30;89(4):e485. doi:10.20883/medical.e485



© 2020 by the author(s). This is an open access article distributed under the terms and conditions of the Creative Commons Attribution (CC BY-NC) license. Published by Poznan University of Medical Sciences

ABSTRACT

Near-infrared spectroscopy allows the measurement of cerebral oxygenation in preterm infants. This study aimed to demonstrate several highly relevant clinical situations in preterm infants in which the standard set of monitoring parameters without near-infrared spectroscopy is not sufficient to detect possible adverse situations, possibly resulting in severe complications, i.e. adverse neurological outcomes. The examples include situations of low blood pressure, persistent open ductus arteriosus, malfunctioning autoregulation of the brain oxygenation, and periods of irregular breathing. Without near-infrared spectroscopy, it is impossible to determine whether such a situation imposes any risk for the brain, whereas the measurement of cerebral oxygenation as an additional source of information enables the clinician to recognise these conditions and modify treatment or use countermeasures to protect the patient from brain damage and ensuing lifelong disabilities.

Introduction

Tissue oximetry using near-infrared spectroscopy (NIRS) is a well-established technology. Its most prominent field of application is pulse oximetry, commonly known as the "finger clips" which are fixed to hospitalised patients in many conditions, and procedures to measure oxygen in the arterial circulation. This technology is attractive to clinicians and patients because it is non-invasive and harmless, simply using low-power light sources to obtain vital clinical information from light travelling through human tissue.

NIRS oximetry uses a similar principle, focusing on the *local* oxygenation of the tissue underneath the sensor. Pulse oximetry assesses the arterial oxygenation, which reflects adequate ventilation, whereas NIRS oximetry provides the tissue oxygen saturation, which reflects the balance of oxygen supply and consumption at the measurement location and is crucial to determine whether an organ is adequately oxygenated. It is used to monitor specific high-risk body parts and organs, such as the brains of preterm children. These patients have taken their first steps into life with underdeveloped lungs and an extreme-

ly fragile overall condition, hence, early death or long-term complications for survivors are a considerable threat. The brain is of particular concern because it is highly sensitive to a lack (or even an excess) of oxygen. When lesions occur, the brain does not heal well, consequently, lifelong disabilities occur constituting the most severe complication for preterm infants.

This paper summarises some of the key benefits of the additional use of cerebral oximetry for newborn preterms compared to their regular treatment.

Materials and Methods

For this Review Article, findings from two influential publications on the effects of NIRS in the care of preterm neonates were used. First, the regular treatment which is typically applied on neonatal units is outlined, then, four typical clinical scenarios are investigated, each of them without and with cerebral oxygenation information available to the medical staff.

Results & Discussion

In all four investigated scenarios, it was shown that the availability of cerebral oxygenation as an additional measurement parameter is advan-

tageous for medical staff, as dangerous clinical situations can be avoided and treatment errors reduced.

Regular treatment

Commonly, patients on neonatal intensive care units (NICUs) are monitored using the following methods and tools:

- › Heart rate measurement
- › Temperature measurement
- › Transcutaneous oxygen (O₂) / carbon dioxide (CO₂) measurement
- › Arterial oxygenation measurement (pulse oximetry) (SpO₂ or SaO₂)
- › On-demand blood gas analyses

These vital signs monitoring enables the application of the necessary treatment to keep the infant alive. Please note that the brain, although being the most sensitive organ to hypoxia, is not considered by these methods. In the next sections, various clinical scenarios will be illustrated, with comparisons between clinical assessment without and with brain oxygenation monitoring being used.

Scenario 1: Low blood pressure

In preterm neonates, as a rule of thumb, a minimum blood pressure of 30 mmHg is considered acceptable [3]. However, low blood pressure occurs frequently and raises the question of whether to treat it (**Figure 1**).

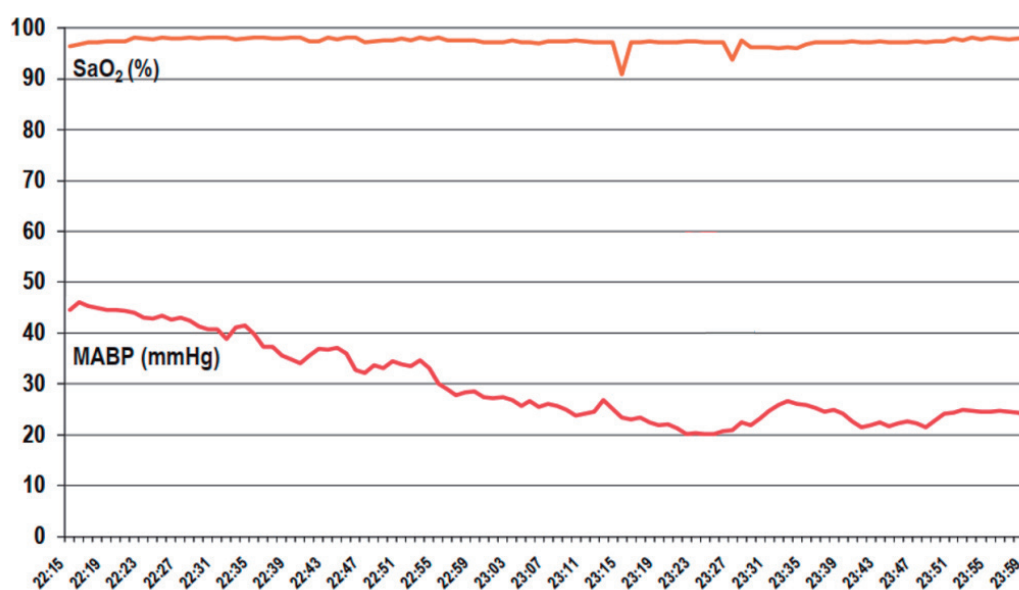


Figure 1. MABP, cerebral oxygenation (StO₂) curve removed for illustrative purposes. Original chart: Wolf, Naulaers, van Bel, Kleiser, Greisen. JNIRS 20, 43–55 (2012) open access.

The arterial oxygenation (SaO_2 measured by the pulse oximeter) does not react to the blood pressure (MABP) dropping below 30 mmHg. The downward spikes in SaO_2 around 23:15 and 23:27 are most likely movement artefacts. For the clinician, it is very difficult to assess the situation and decide on treatment, as the consequence of the low blood pressure is not visible in any of the available parameters (**Figure 2**).

In contrast, cerebral oxygenation (StO_2 measured by the NIRS monitor) is affected by the dropping blood pressure. A StO_2 level below 55% is considered dangerous [4], indicating to the clinician that due to the low blood pressure, the oxygen supply to the brain is dangerously low and not adequate for the brain's oxygen consumption, hence, treatment for low blood pressure is required. Several well-known treatment

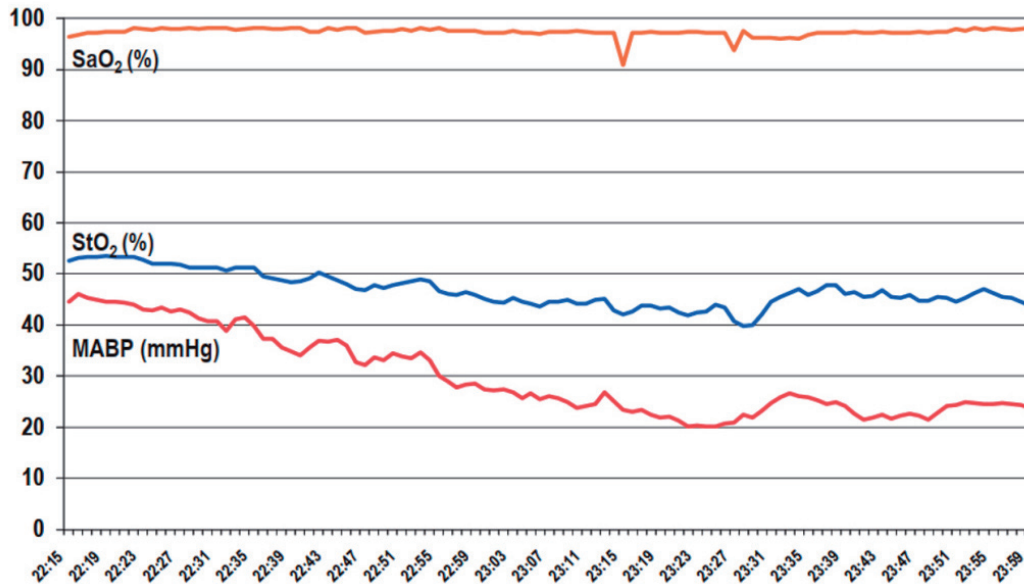


Figure 2. MABP including cerebral oxygenation (StO_2) curve. Chart: Wolf, Naulaers, van Bel, Kleiser, Greisen. JNIRS 20, 43-55 (2012) open access

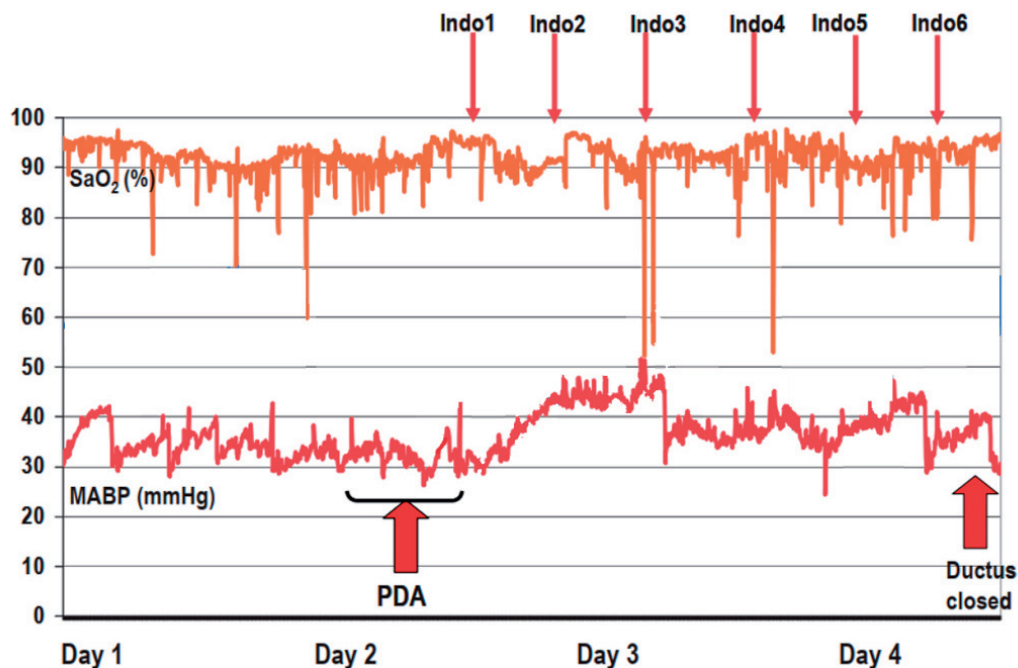


Figure 3. Treatment of a ductus arteriosus, cerebral oxygenation (StO_2) curve removed for illustrative purposes. Original chart: Wolf, Naulaers, van Bel, Kleiser, Greisen. JNIRS 20, 43-55 (2012) open access.

options are available for this, therefore, by using StO_2 , the decreasing brain oxygen levels can be recognised and treated before brain damage occurs.

Scenario 2: Ductus arteriosus

A persistent open ductus arteriosus (PDA) allows venous blood with low oxygenation to enter the arteries, thus hampers the oxygen supply to the body. When a PDA occurs, clinicians often use drugs, such as Indometacin, to constrict and close the ductus without having to perform surgery (Figure 3).

In this baby, six doses of Indometacin ("Indo1" to "Indo6") were administered after the occurrence of the PDA. Blood pressure (MABP, consistently over 30 mmHg) and arterial oxygenation (SaO_2 , consistently around or above 90%, with occasional movement artefacts) were of no concern (Figure 4).

The addition of cerebral oxygenation measurement (StO_2) shows that several oxygen undersupply situations occur due to the PDA and during its treatment, thus the clinician can recognise that this situation is dangerous for the brain and apply countermeasures earlier.

Scenario 3: Impeded autoregulation

Autoregulation is the capability of the human brain to self-adjust to changing blood pressure to maintain stable oxygenation, however, often preterm neonates cannot autoregulate well (Figure 5).

The above chart shows that the blood pressure (MABP) fluctuates in two patients, one with impeded autoregulation (top) and one with working autoregulation (bottom) but arterial oxygenation (SaO_2) levels remain in the desired range, hence, there is no cause for concern. However, assessing the cerebral autoregulation without cerebral oxygenation measurement is impossible only from the changes in blood pressure and arterial oxygenation (SaO_2) (Figure 6).

In the upper chart, the blood pressure changes directly lead to brain oxygenation changes, indicating impaired autoregulation, thus a higher risk for cerebral lesions. This patient suffers from several periods of brain oxygen undersupply (hypoxia), whereas the patient in the lower chart shows no effect of the substantial blood pressure changes on the brain oxygenation (rScO_2). This is a sign of intact autoregulation and this infant is much less at risk for brain lesions. By measur-

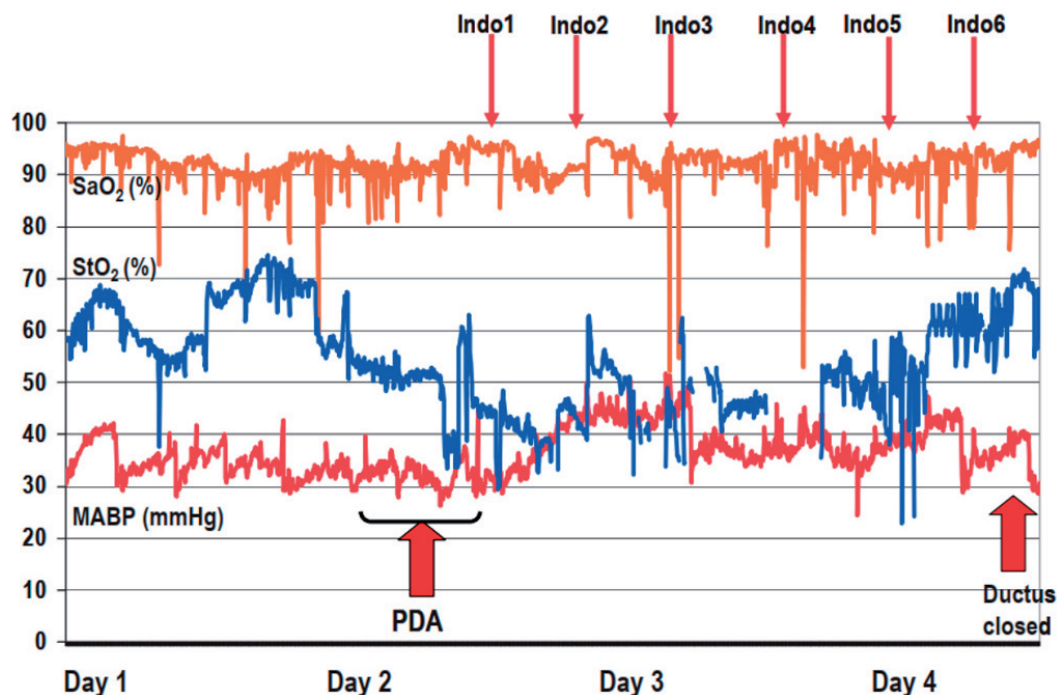


Figure 4. Treatment of a ductus arteriosus including cerebral oxygenation (StO_2) curve. Chart: Wolf, Naulaers, van Bel, Kleiser, Greisen. JNIRS 20, 43–55 (2012) open access

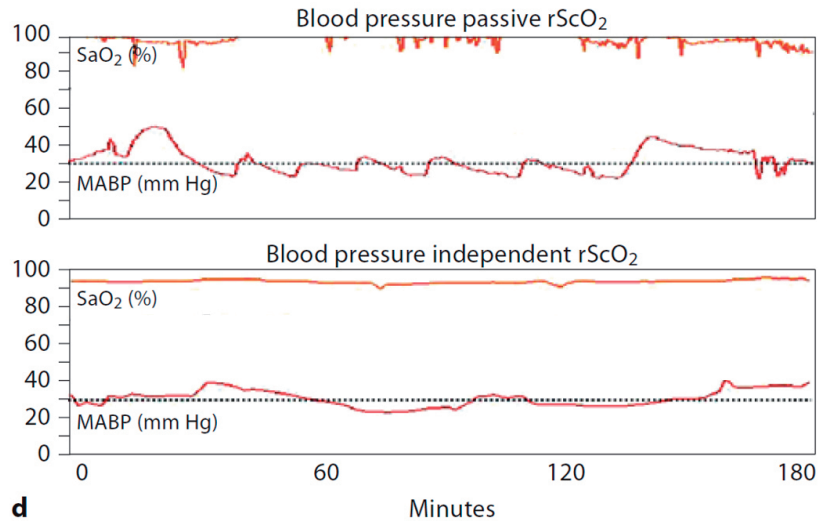


Figure 5. Impeded autoregulation, cerebral oxygenation (rScO₂) curve removed for illustrative purposes. Original chart: van Bel, Lemmers, Naulaers, *Neonatology* 2008;94:237–244

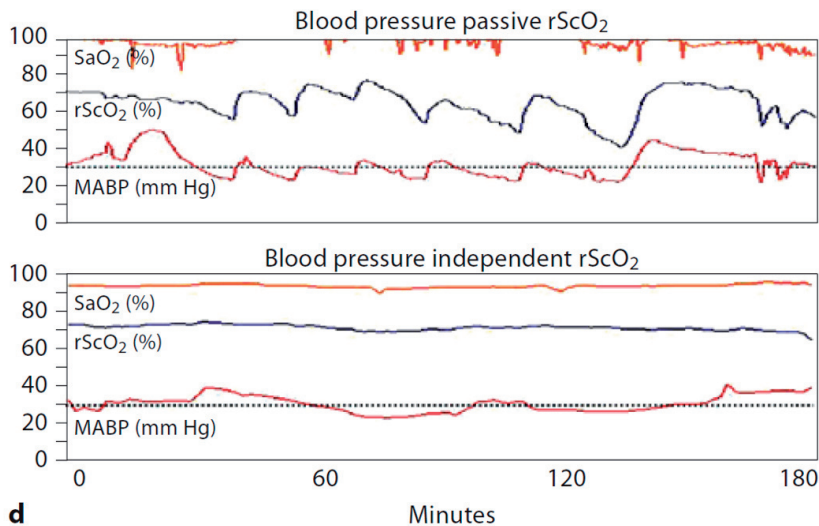


Figure 6. Impeded autoregulation including cerebral oxygenation (rScO₂) curve. Chart: van Bel, Lemmers, Naulaers, *Neonatology* 2008;94:237–244

ing cerebral oxygenation, the clinician becomes aware of these situations and can take measures to prevent brain lesions.

Scenario 4: O₂ administration during apnoea

Preterms often suffer from apnoea, that is, their breathing stops for a certain period, with no oxygen is supplied to the body during that time (**Figure 7**).

Here, the arterial oxygenation (SaO₂) shows the phases of apnoea and this condition was treated by administering additional oxygen. Therefore, this condition was detectable using standard SaO₂ measurement (**Figure 8**).

At points 1, 2, 3, and 4, additional oxygen is administered to the patient, i.e. the inspired oxygen fraction (FiO₂) is increased, with the SaO₂ returning to normal levels at each time point. However, adding the measurement of cerebral oxygenation (rScO₂ here) reveals that the brain oxygenation is *too high* >85% after this FiO₂ is increased (points 2, 3, and 4). This means that too much oxygen was given, resulting in over-oxygenation (hyperoxia) which can cause blindness, a constriction of the brain blood vessels and other adverse events. This threat would remain hidden to the clinicians without cerebral oximetry.

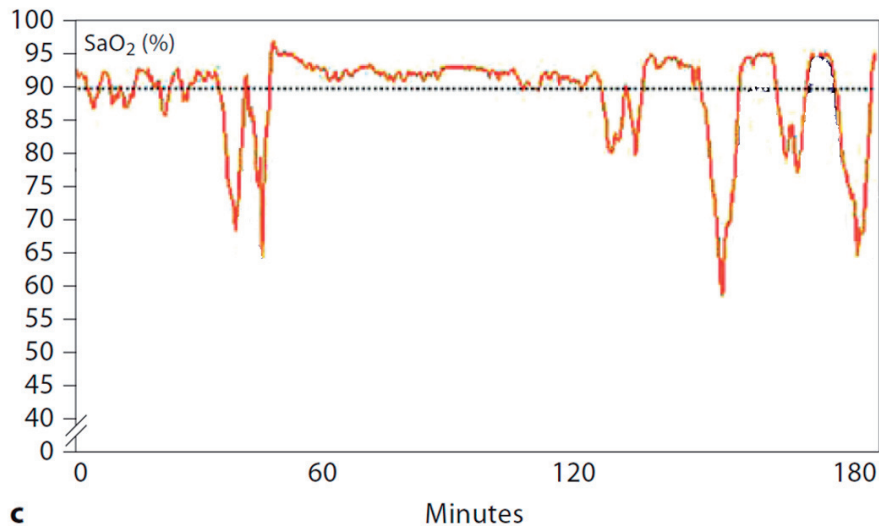


Figure 7. O₂ administration during apnoea, cerebral oxygenation (rScO₂) curve removed for illustrative purposes. Original chart: van Bel, Lemmers, Naulaers, Neonatology 2008;94:237–244

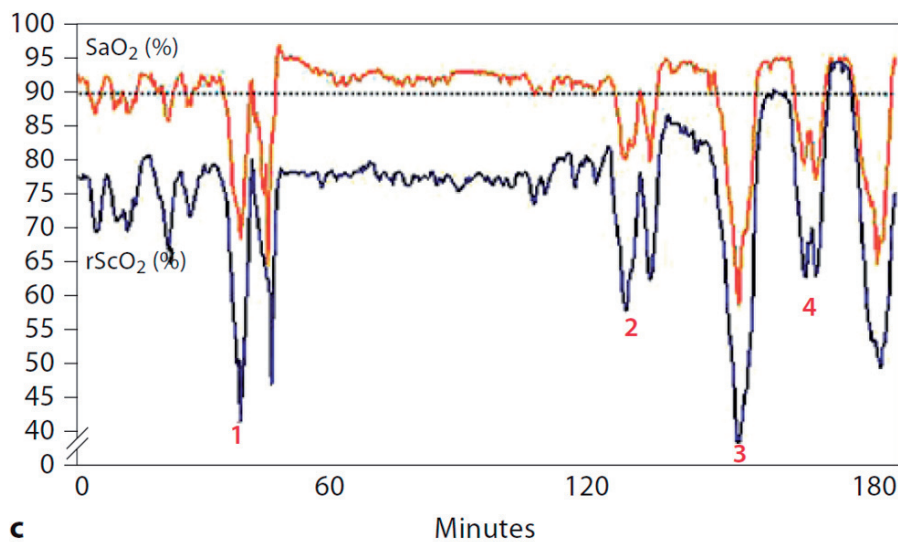


Figure 8. O₂ administration during apnoea including cerebral oxygenation (rScO₂) curve. Chart: van Bel, Lemmers, Naulaers, Neonatology 2008;94:237–244

Conclusion

NIRS oximetry provides useful and potentially life-saving additional information to medical professionals.

This review presented four examples of common medical conditions in neonatal care: *Low blood pressure* (Scenario 1), *persistent ductus arteriosus* (Scenario 2), *impeded autoregulation* (Scenario 3), and *apnoea* (Scenario 4).

Using only standard clinical parameters in these conditions, the clinician incurs the risk of at

least one of the following two unwanted effects 1) dangerous situations may remain undetected and 2) treatment errors may occur. This may lead to potentially severe adverse outcomes, such as premature death as well as brain damage leading to lifelong disabilities, paralysis, cerebral palsy and/or learning/developmental impairments. Therefore, it is vital to further improve the quality of care for these high-risk patients wherever possible.

Adding NIRS oximetry to the routine set of monitoring parameters in neonatal care is an effective option: For every one of the four pre-

sented medical conditions, the usefulness of continuous cerebral oxygenation monitoring was demonstrated, hence, cerebral oxygenation monitoring is an important step towards improved clinical care for preterm infants. This enables not just a higher survival rate but also a better neurological outcome, therefore creating long-term benefits for the patients, their families, as well as public and private health systems.

Acknowledgements

Conflict of interest statement

Saudamini NESARGI: No conflicts of interest.

Alexander NITSCH: CEO of OxyPrem AG, a Swiss company active in the field of developing novel NIRS monitoring equipment for clinical use.

Martin WOLF: Chairman of the Board of OxyPrem AG, a Swiss company active in the field of developing novel NIRS monitoring equipment for clinical use..

Funding sources

There are no sources of funding to declare.

References

1. van Bel F, Lemmers P, Naulaers G. Monitoring Neonatal Regional Cerebral Oxygen Saturation in Clinical Practice: Value and Pitfalls. *Neonatology*. 2008;94(4):237–244. <https://doi.org/10.1159/000151642>
2. Wolf M, Naulaers G, van Bel F, Kleiser S, Greisen G. A Review of near Infrared Spectroscopy for Term and Preterm Newborns. *Journal of Near Infrared Spectroscopy*. 2012 Jan;20(1):43–55. <https://doi.org/10.1255/jnirs.972>
3. Fanaroff JM, Fanaroff AA. Blood pressure disorders in the neonate: Hypotension and hypertension. *Seminars in Fetal and Neonatal Medicine*. 2006 Jun;11(3):174–181. <https://doi.org/10.1016/j.siny.2006.01.002>
4. Hyttel-Sorensen S, Austin T, van Bel F, Benders M, Claris O, Dempsey E, Fumagalli M, Greisen G, Grevstad B, Hagmann C, Hellström-Westas L, Lemmers P, Lindschou J, Naulaers G, van Oeveren W, Pellicer A, Pichler G, Roll C, Skoog M, Winkel P, Wolf M, Glud C. A phase II randomized clinical trial on cerebral near-infrared spectroscopy plus a treatment guideline versus treatment as usual for extremely preterm infants during the first three days of life (SafeBoosC): study protocol for a randomized controlled trial. *Trials*. 2013;14(1):120. <https://doi.org/10.1186/1745-6215-14-120>