



## THOUSAND WORDS ABOUT...

DOI: <https://doi.org/10.20883/jms.2017.150>

# Endoleaks after endovascular abdominal aortic aneurysm repair

Jakub T. Kramek<sup>1</sup>, Hubert Stępak<sup>2</sup>, Grzegorz Oszkinis<sup>2</sup>

<sup>1</sup> WL I, 2<sup>nd</sup> year, Poznan University of Medical Sciences, Poland

<sup>2</sup> Department of General and Vascular Surgery, Poznan University of Medical Sciences, Poland

### ABSTRACT

Traditional surgical repair and endovascular repair (EVAR) are the treatment options for abdominal aortic aneurysm repair. EVAR as less invasive becomes a significant and widely accepted way of treatment aortic aneurysms with expanding number of procedures. This technique has a lower short-term mortality and a shorter hospital stay but is not free from complications. The most common complication after EVAR are endoleaks. For the first time summarised and assessed in 1997. Although it is often asymptomatic but may cause aneurysm expanding and rupture. Endoleak is defined as persistent blood flow into the aneurysm sac. It can be revealed intra-operatively or during the follow up – CT; arteriography, angio-MRI enables endoleak diagnosis. Usage of duplex sonography is questionable. In this mini-review we summarise endoleak diagnostic, classification and treatment options.

**Keywords:** Endoleak, EVAR, Abdominal Aortic Aneurysm (AAA).

Traditional surgical repair and endovascular repair (EVAR) are the treatment options for abdominal aortic aneurysm repair [1]. EVAR as less invasive becomes a significant and widely accepted way of treatment aortic aneurysms with expanding number of procedures [2]. This technique has a lower short-term mortality and a shorter hospital stay but is not free from complications. The most common complication after EVAR are endoleaks [3]. For the first time summarised and assessed in 1997 [4]. Although it is often asymptomatic but may cause aneurysm expanding and rupture.

Endoleak is defined as persistent blood flow into the aneurysm sac. It can be revealed intra-operatively or during the follow up – CT; arteriography, angio-MRI enables endoleak diagnosis [4]. Usage of duplex sonography is questionable [5].

In this mini-review we summarise endoleak diagnostic, classification and treatment options.

## Classification

Due to their etiology, endoleaks are divided into five groups [5–7] (Table 1, Figure 1).

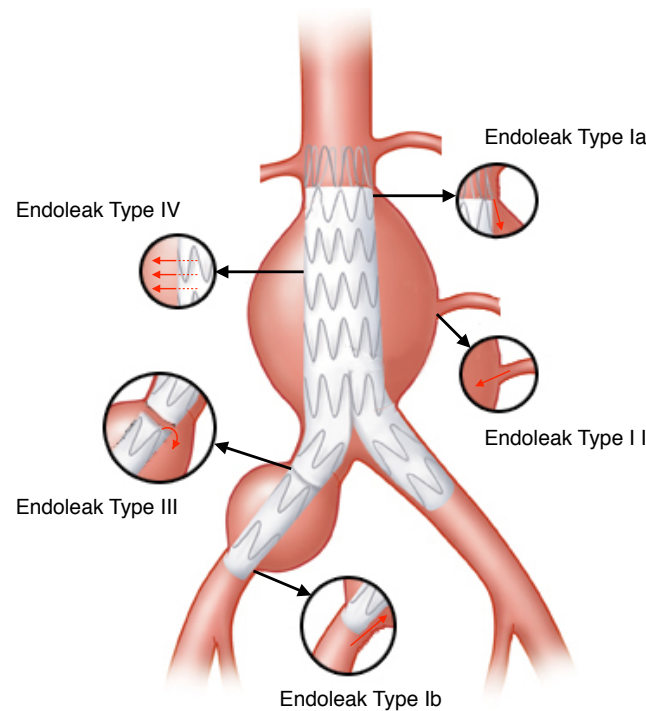
**Type I** endoleak results from incompetent seal at the proximal or distal end of the endograft. Blood enters the aneurysm sac through the leakiness between the graft and aortic mural. Causes of type I endoleaks are usually inadequate selection of patients (tortuosity, neck length and diameter), improper graft size, graft migration or improper placement of the graft due to incorrect imaging techniques parallax. This kind of endoleaks are often revealed intra-operatively, enabling immediate repair. Intervention should be prompt especially when sac enlargement is observed, because aneurysm rupture is probable. Type I endoleaks appears in up to 10% after EVAR procedures [5].

**Type II** endoleak develops as a result of retrograde blood flow into the aneurysm sac, through a patent lumbar arteries, inferior mesenteric artery or internal iliac artery (hypogastric artery). It is the most common complication after EVAR – in 25% of cases [5]. It often disappears as the vessel thromboses, self-limiting. When no sac enlargement is detected, observation is recommended.

**Type III** endoleak occurs due to fracture, hole, defect of the graft fabric, separation or mismatch of

**Table 1.** Classification of endoleaks

Type I (incompetent seal)	Type II (patent branches)	Type III (graft defect)	Type IV	Type V
Ia – proximal	IIa – 1 vessel	IIIa – graft components separation	leakage through grafts fabric porosity	sac diameter increasing with no endoleak detected
Ib – distal	IIb – 2 or more vessels	IIIb – grafts holes / fractures	–	–
Ic – iliac occluder	–	–	–	–



**Figure 1.** Classification of endoleaks

the graft components. It is as severe condition as type I endoleak, and also in this case repair is mandatory.

**Type IV** endoleak is an outcome of endografts fabric porosity. Osmotic pressure creates a exudation of molecules through a grafts wall into the aneurysm sac. It usually resolves spontaneously, and require no treatment.

**Type V** endoleak is also referred as the endotension which is defined as aneurysm sac pressure raising with no evidence of endoleak. The etiology of endotension is uncertain. Some authors suggest transmission of the systemic pressure through the graft wall and the aneurysm sac to the aneurysm wall.

### Follow up and modality [5, 6]

Contrast enhanced CT angiography (CTA) is a gold standard for aneurysm sac diameter measurement [6]. CTA is the best modality for endoleak detection and its sensitivity exceeds duplex ultrasonography [5, 6]. CTA also allows to reveal stent migration or fracture.

MRI/MRI angiography are comparable to CTA. Pros of MRI is avoidance of nephrotoxicity and ionising radiation, whereas cons are high price of procedure and contraindications for patients with cardiac pacemakers and metal artefacts.

Plain radiographs, (A-P and lateral projections) enables detection of sent fracture or migration.

Contrast-enhanced duplex ultrasonography (CDU) is supposed to be a safe tool for endoleak detection [8]. Important benefit from usage of this modality is blood flow exposure.

Sac pressure measurement – It is an invasive technique and does not indicate for AAA and endoleak evaluation, thus its value is not clear [5–7].

According to ESVS guidelines [6], follow-up schedule is as follows:

- CTA and plain abdominal radiographs, conducted 30 days postoperatively.
- Endoleak / < 1 stent component / poor overlap – CTA and plain radiographs at 6 and 12 months postoperatively.

- No endoleak and good overlap – CTA and plain radiographs at 12 months postoperatively.
- If there is no endoleak evidence at 12 months, DU and plain radiographs are recommended. Any endoleak or sac diameter increase should be confirmed with CTA.
- DU / non-contrast CT / plain radiographs – might be a solution for patients with renal failure.

## Treatment [5, 6, 9, 10]

**Type I endoleaks** – discovered intra-operatively, re-ballooning of the landing sites is the method of choice [6]. When this procedure fails or endoleak is detected during the follow up, recommended treatment is usage of additional stent-grafts which seals the leaking end and exclude the aneurysm sac from the circulation. In some cases coil embolisation of a leak is feasible. If endovascular methods of treatment are insufficient, or endoleak is detected intra-operatively, conversion to the open method might be needed [10].

**Type II endoleaks** – as mentioned before a significant part of type II endoleaks resolves spontaneously [5, 6]. It is questionable whether management of type II endoleaks with no remarkable diameter changes is an appropriate way of treatment [5, 6]. In this case increased observation is suggested [6].

When 10 mm/year or bigger sac diameter enlargement is observed, coil embolization of patent branches is a possible solution whereas translumbar embolization is feasible and gives good early and long term results [5]. Third way of treatment is laparoscopic cessation of retrograde blood flow [5]. When excluded aneurysm sac is filled through a hypogastric artery at the level of common iliac artery, its unilateral ligation is justified [5]. In this particular case, administration of extra cuffs or endovascular embolization are also possible ways of treatment

**Type III endoleaks** – due to a threat of sac rupture this kind of leaks are treated immediately after detection, usually by placement an additional stent-grafts [6, 9]. If treatment is refractory for endovascular methods open surgery should be considered.

**Type IV endoleaks** – usually resolve spontaneously and require no intervention [6].

**Type V endoleaks (endotension)** – Asymptomatic cases management is controversial [5, 6]. When aneurysm sac enlargement is observed, additional stent-grafts insertion is advocated.

## Acknowledgements

### Conflict of interest statement

The authors declare no conflict of interest.

### Funding sources

There are no sources of funding to declare.

## References

1. Kent KC. Clinical practice. Abdominal aortic aneurysms. *N Engl J Med*. 2014 Nov 27;371(22):2101–8.
2. Blankensteijn JD, de Jong SE, Prinssen M, van der Ham AC, Buth J, van Sterkenburg SM et al. Two-year outcomes after conventional or endovascular repair of abdominal aortic aneurysms. Dutch Randomized Endovascular Aneurysm Management (DREAM) Trial Group *N Engl J Med*. 2005 Jun 9;352(23):2398–405.
3. Liaw JV, Clark M, Gibbs R, Jenkins M, Cheshire N, Hamady M. Update: Complications and management of infrarenal EVAR. *Eur J Radiol*. 2009 Sep;71(3):541–51.
4. White GH, Yu W, May J. Endoleak as a complication of endoluminal grafting of abdominal aortic aneurysms: classification, incidence, diagnosis, and management. *J Endovasc Surg*. 1997 May;4(2):152–68.
5. Frank J Veith, MD, Richard A. Baum, MD, Takao Ohki, MD, Max Amor. Nature and significance of endoleaks and endotension: Summary of opinions expressed at an international conference. *J Vasc Surg*. 2002 May;35(5):1029–35.
6. Moll FL, Powell JT, Fraedrich G, Verzini F, Haulon S, Waltham M. Management of Abdominal Aortic Aneurysms Clinical Practice Guidelines of the European Society for Vascular Surgery. *Eur J Vasc Endovasc Surg*. 2011 Jan;41(Suppl. 1):S1–S58.
7. White GH, May J, Waugh RC, Chafour X, Yu W. Type III and type IV endoleak: toward a complete definition of blood flow in the sac after endoluminal AAA repair. *J Endovasc Surg*. 1998;5:305e9
8. Mirza TA, Karthikesalingam A, Jackson D, Walsh SR, Holt PJ, Hayes PD et al. Duplex ultrasound and contrast-enhanced ultrasound versus computed tomography for the detection of endoleak after evar: systematic review and bivariate meta-analysis. *Eur J Vasc Endovasc Surg*. 2010;39:418e28.
9. Faries PL, Cadot H, Agarwal G, Kent KC, Hollier LH, Marin ML. Management of endoleak after endovascular aneurysm repair: cuffs, coils, and conversion. *J Vasc Surg*. 2003;37:1155e61.
10. Kelso RL, Lyden SP, Butler B, Greenberg RK, Eagleton MJ, Clair DG. Late conversion of aortic stent grafts. *J Vasc Surg*. 2009;49:589e95.

Acceptance for editing: 2016-12-10  
Acceptance for publication: 2017-03-27

### Correspondence address:

Jakub Kramek  
68/20 Przemysłowa Street, 61-541 Poznań Poland  
phone: +48 790876477  
email: jakub\_kramek@onet.eu